

## Evaluation of Dexmedetomidine as an Additive to Ropivacaine for Popliteal Approach for Sciatic Nerve Block for Foot Surgeries

Pallavi Ahluwalia<sup>1</sup>, Payal Jain<sup>2</sup>, Amit Ahluwalia<sup>3</sup>

<sup>1</sup>Professor <sup>2</sup>Assistant Professor, Department of Anaesthesia, Teerthanker Mahaveer Medical College, Moradabad, Uttar Pradesh 244001, India. <sup>3</sup>Consultant Orthopaedics, Kothiwal Dental College and Research Hospital, Moradabad, Uttar Pradesh 244001, India.

### Abstract

**Introduction:** Peripheral nerve blocks are used in varieties of surgical and diagnostic procedures. Various methods or approaches have been tried to prolong the duration of nerve blocks. Dexmedetomidine acts selectively on alpha-2 adrenergic receptor agonist and can be a promising adjuvant to local anaesthetics. Our study evaluates the clinical efficacy of dexmedetomidine added to Ropivacaine for sciatic nerve block. **Material and Methods:** Patients undergoing foot surgeries were divided randomly into two groups. Group RS ( $n = 30$ ): received 19.5 ml of 0.75% Ropivacaine and 0.5 ml saline for sciatic nerve block via popliteal approach and Group RD ( $n = 30$ ): received 19.5 ml of 0.75% Ropivacaine with 0.5 ml (50 mg) of dexmedetomidine. **Result:** The onset time of sensory block (mean) in minutes was  $8.64 \pm 2.4$  in RS Group,  $5.78 \pm 2.7$  in RD Group ( $p < 0.001$ ). The mean time for onset of motor block, in minutes, was  $10.42 \pm 3.6$  in RS Group,  $8.78 \pm 1.7$  in RD Group ( $p < 0.001$ ). The difference in regards to duration of sensory and motor block was statistically significant, with RD Group faring better than RS Group. The mean time to rescue analgesia, in minutes, was  $339.8 \pm 29.31$  in Group RS and  $512.43 \pm 30.92$  in Group RD ( $p < 0.001$ ). The quality of anaesthesia was better and sedation scores were more in group RD versus group RS. **Conclusion:** The overall quality of anesthesia achieved with 50  $\mu$ g dexmedetomidine as an additive to 0.75% Ropivacaine is more effective in terms of duration and intensity of analgesia in comparison to 0.75% Ropivacaine alone.

**Keywords:** Adrenergic  $\alpha$ 2-Receptor Agonists; Ultrasonography; Dexmedetomidine; Sciatic Nerve.

### How to cite this article:

Pallavi Ahluwalia, Payal Jain, Amit Ahluwalia. Evaluation of Dexmedetomidine as an Additive to Ropivacaine for Popliteal Approach for Sciatic Nerve Block for Foot Surgeries. Indian J Anesth Analg. 2018;5(11):1872-79.

### Introduction

Nerve block, now a day's is a very commonly used regional anaesthesia technique in various procedures ranging from diagnostic to surgical and interventional ones. There are a few limitations which are inherent to perioperative peripheral nerve block techniques like the duration of block is limited and hence patient may require analgesics early in postoperative period. Along with that, there is possibility of side effects of opioids on the central

nervous, hemodynamic and respiratory systems.

Various methods or approaches can be tried to enhance the duration of nerve block. One good alternative is Continuous catheter technique, but it has logistical challenges like continuous observation of catheter is required and its associated complications such as catheter displacement [1] and infection [2-4]. Other alternatives include addition of adjuvant drugs such as alpha-2 adrenergic receptor agonists, opioids, ketamine, dexamethasone to increase block duration [5-6].

**Corresponding Author:** Pallavi Ahluwalia, Professor, Department of Anaesthesia, Teerthanker Mahaveer Medical College, Moradabad-244001, U.P., India.  
E-mail: [drpallaviahlwalia@yahoo.com](mailto:drpallaviahlwalia@yahoo.com)

Received on 08.08.2018, Accepted on 17.09.2018

Dexmedetomidine [7,8] is a highly selective alpha-2 adrenergic receptor agonist with various properties such as analgesic, sympatholytic, sedative and amnestic. Various studies have been published which include both clinical and Experimental trials, with various doses ranging between 20 and 150 µg of Dexmedetomidine as an additive to local anaesthetics [1,9-14]. In 2004, Dexmedetomidine was used for the first time as an additive to supplement intravenous regional anesthesia [15]. In recent years, it has been investigated and found effective in both clinical studies [7] and animal models as an adjuvant to local anaesthetics during peripheral nerve blockade [17,18]. Esmaglu et al. [19] reported improvement in the quality of the block (that is early onset time and extended duration of block) in their axillary brachial plexus block in which dexmedetomidine was used as an adjuvant to levobupivacaine. Brummett et al. [17] also found that adding dexmedetomidine to Ropivacaine caused nearly 75% increase in analgesic duration in rats. However, the investigations are confined to a single terminal nerve branches like ulnar nerve or brachial plexus blockade for upper extremity block [20]. The combination of dexmedetomidine with local anaesthetics for nerve block, helps to prolong the time to first use of systemic analgesia which makes it clinically relevant. Therefore we designed our present prospective, randomised and double blinded study to evaluate the block characteristics of Ropivacaine alone, and with dexmedetomidine (50 µg) as adjuvant for popliteal approach to sciatic nerve block (PSNB) and its effect on block characteristics like sensory and motor onset and duration. We used a surrogate pharmacodynamic parameter (i.e. duration of sensory blockade) in the present study to evaluate the addition of dexmedetomidine to Ropivacaine for this nerve block.

## Material and Methods

The present study was carried out in our institute over a period of 1 year from Jan 2017 to Dec 2017. After ethical committee approval, Written and informed consent was obtained from the patients for their participation in the present study. Patients of both sexes, with American Society of Anaesthesiologists (ASA) physical status I and II, between 18 and 60 years, undergoing foot surgeries, were enrolled in our study. Patients were randomized to receive sciatic nerve block via popliteal approach and were randomly allocated into two groups. The

patients, who consented, were divided into two groups, by allocating them a random number by chit in the box method. Sixty patients were allocated into one of the groups: Group RS ( $n = 30$ ): Received 19.5 ml of 0.75% Ropivacaine and 0.5 ml normal saline. Group RD ( $n = 30$ ): Received 19.5 ml of 0.75% Ropivacaine with 0.5 ml (50 µg) dexmedetomidine for nerve block anaesthesia. Popliteal block was performed under USG guidance. Patient was observed for 24 hrs.

### *Inclusion Criteria*

Patients who were scheduled for elective foot surgeries such as debridement of foot/ankle and toe surgeries were screened.

### *Exclusion Criteria*

Patient refusal, diabetes mellitus, history of allergy to local anaesthetic or dexmedetomidine, infection at site of injection site, psychiatric disorders or likely to be uncooperative during surgery, patients already treated with alpha2 adrenoreceptor agonist, pregnant patients were excluded.

Baseline hemodynamic parameters, heart rate, NonInvasive Blood Pressure (NIBP), Mean Arterial Pressure (MAP), pulse oximetry, respiratory rate, and temperature were recorded. ASA standard monitors were attached (pulse oximeter, ECG, NIBP, RR, temperature). Patients were premedicated with i.v. midazolam 1.5 mg before performing block to allay anxiety. Ultrasonography-guided sciatic Nerve Block Technique via popliteal approach- After intravenous (IV) access, patient was turned to lateral decubitus position and skin preparation was done with povidone-iodine. In the popliteal fossa, the sciatic nerve was identified by ultrasonography (Sonosite) using a linear array 6 to 15-M Hz ultrasonography probe. Nerve was visualised along its course till it divides into the tibial nerve and common peroneal nerve. After skin infiltration with local anaesthetic, a 21-G short-bevel insulated needle was inserted and advanced under a short axis view of the target utilizing an in-plane needling approach. The LA mixture was then deposited under direct ultrasonographic visualization (total volume of 20 mL) inside the fascial plane of the common peroneal sheath, below and above the sciatic nerve at the point where the tibial nerve and common peroneal nerve unite. "Donut" signs indicated successful distribution of the study solution around the posterior tibial nerve and the common peroneal nerve. The mixture was injected in 5-mL aliquots with intermittent confirmation of negative blood aspiration.

Ropivacaine was chosen as the local anaesthetic because of its favorable clinical [21,22] and toxicity profile [23]. Of the available concentrations, the 0.75% concentration was selected based on previous studies [21,24]. Ropivacaine 0.75% (19.5 mL) was mixed with either 0.5 mL of saline (control group) and 0.5 mL of dexmedetomidine (50 mcg), according to randomization. The drug or the mixture was prepared by the pharmacist (blinded) and the blinded block performer was blinded also. In total, 20 mL of local anaesthetic mixture was injected. Two anaesthesiologists, experienced with the popliteal block performed all blocks. An assistant blinded to group allocation evaluated sensory and motor block every 2 minutes after injection till 20 minutes and every 5 minutes i.e 25 and 30 min.

#### Parameters

*Assessment of Sensory and Motor Blockade-* The onset of Sensory and motor block and the duration of the block were noted by observer. The baseline assessment was done before block placement. Second, the onset of sensory and motor block was assessed at 2-minute intervals starting 2 minutes after block placement upto 20 minutes, then again at 25 and 30 minutes after the sciatic nerve block. The onset time for sensory or motor block, more than 30 minutes was determined as a failed block. The sensory and motor block duration was assessed at the end of surgery and then at 2, 4, 6, 8, and 24 hours to avoid disturbing patient's sleep in wards after surgery. Evaluation of sensory and motor block duration was done by asking a set of questions: "When did the patient start to feel sensation returning in the foot," "The time at which pain was felt in the foot," and "Time at which patient could move toes on the operated side?". Inj. Paracetamol 1 gm was given as first rescue analgesic for the patients requiring supplemental analgesia in wards. Sensory assessment of nerve block was performed in dermatomal area using pinprick test (contralateral extremity was taken as a control). Motor blockade was then assessed using a 3-point scoring system, with 0- indicating normal muscle power or 5/5; 1- reduced muscle power (2 to 4/5); only plantar or dorsiflexion; and 2-complete motor block (0/5) no plantar and dorsal flexion.

Onset of motor block and duration were identified as follows: onset of motor block from the end of injection to complete motor blockade and motor block duration from the end of injection to complete return of baseline motor strength.

*Evaluation of quality of Surgical Anaesthesia -* Quality of surgical anaesthesia was assessed and divided into 1 of 3 levels as follows: 1, excellent (complete surgical anaesthesia without the requirement of

any supplemental medications); 2, good to intermediate (very mild discomfort requiring very small amounts of sedation, e.g., routine sedation was inj. Midazolam 1.5mg; and 3-poor (block failure that required conversion to general anaesthesia).

*Sedation Score-* sedation level (30 minutes after block) was assessed using the Ramsay sedation scale [25] where 0-2 points represents inadequate sedation, 2 to 4 points indicates satisfactory sedation, and >4 points signify excessive sedation as follows:

1. Patient fully awake and oriented;
2. Patient cooperative, drowsy and tranquil;
3. Patient asleep but responds to oral commands;
4. Asleep but awakened by response to light glabellar tap or auditory stimulus;
5. Asleep and sluggish responding to light glabellar tap or auditory stimulus;
6. Asleep without any response to light glabellar tap or auditory stimulus.

*The onset time for Sensory block onset time:* time from performance of the block to pinprick 0% in dermatomal spread. Duration of sensory block: time during which pinprick 0% persisted in all areas. Complete recovery from sensory block: time from performance of the block to pinprick 100% in all sensory areas. Time to use of first systemic analgesia was recorded. Side effects such as nausea/vomiting, hypotension, bradycardia, pruritus etc were recorded. Hemodynamic parameters were monitored after block till end of surgery.

*Monitoring for Evidence of Adverse Effects-* Commonly observed adverse effects [26] from dexmedetomidine administration are excessive sedation (1 to 6 as defined above), respiratory depression (respiratory rate of 10 breaths/min), nausea, vomiting, hypotension (mean arterial pressure - 20% decrease from baseline), and bradycardia (heart rate of 50 beats/min). Atropine and ephedrine were prepared and kept ready if needed for treatment of hypotension and/or bradycardia.

#### Statistical Analysis

A pilot trial which was conducted initially to assess sciatic nerve sensory block onset time using 5 patients in each group suggested a mean (SD) of 8.6 (3.5) min in the RS group and 12.2 (4.5) min in the RD group. Therefore, a 2-tailed type I error of 5% and type II error of 10% ( $\alpha$  ¼ 0.05,  $\beta$  ¼ 0.1) required, a sample size of 28 patients per group by sample size [PASS] 11.0. Considering potential dropouts, 30 patients were recruited in each group. Student's t test was used

to compare quantitative variables with normal distribution, which included variables like the onset time and duration of sensory and motor blockade. Chi square analysis was used for comparison of categorical variables. All data are presented as mean (SD), and p value of 0.05 was considered statistically significant.

### Results

Eighty five patients were screened and 21 patients were excluded (not meeting inclusion criteria-6, declined to participate -14, other reason -1). 64 patients were randomized and 2 were excluded from each group because of block failure and hence

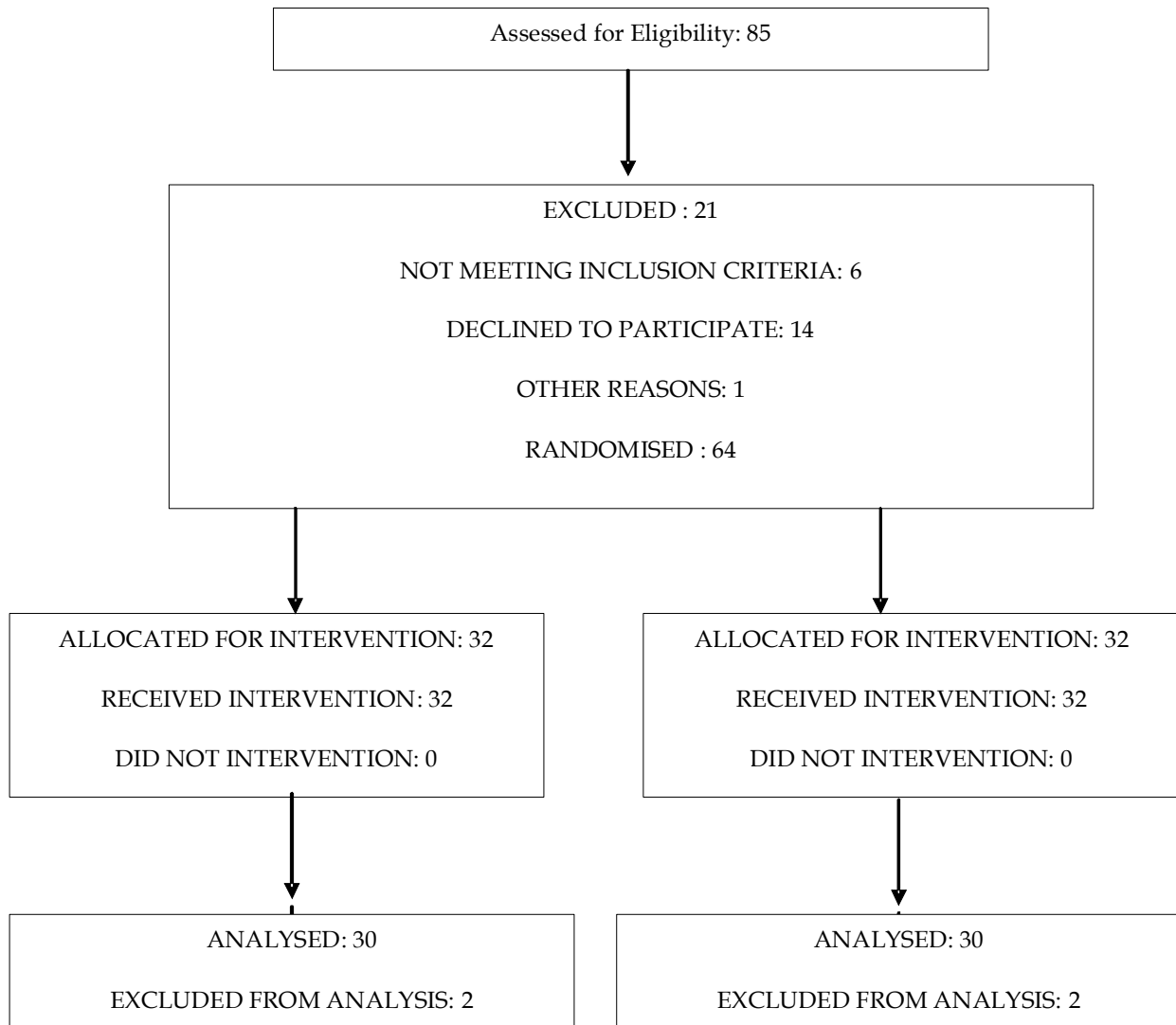


Fig. 1:

**Table 1:** Demographic profile

Groups	Group RS	Group RD	P Value
Mean age ( years)	43.67±13.93	45.63±12.81	0.5428
Duration of surgery(min)	56±10.11	57±11.20	0.6282
Weight (kg)	68.45±9.65	70.71±10.82	0.7064
Height(cm)	166.36±7.59	163.47±8.89	0.5457
Sex (M:F) distribution	14:16	18:12	

**Table 2:** Block variables

Groups	RS group mean (SD)	RD group mean(SD)	P value
Sensory onset time (min)	8.64±2.4	5.78±2.7	<0.001
Motor onset time(min)	10.42±3.6	8.78±1.7	<0.001
Duration of sensory block(min)	323.65±21.23	466.24±29.84	<0.001
Duration of motor block(min)	248.67±28.34	276.41±33.41	<0.001
Time for first analgesic (min)	339.31±29.31	512.43±30.92	<0.001

**Table 3:** Quality of surgical anaesthesia

Anaesthesia characteristics	Group RS	Group RD	P value
Excellent	10	16	<0.001
Good to intermediate	20	14	<0.001
Poor	0	0	0.00

**Table 4:** Sedation score

Sedation score	Group RS	Group RD	P value
0-2	30	26	<0.001
2-4	0	4	<0.001
>4	0	0	0.00

**Table 5:** Side effects

	Group RS	Group RD	P value
Nausea/vomiting	0	0	0.00
Bradycardia	1	2	>0.05
Hypotension	0	0	0.00
Pruritus	0	0	0.00
Shivering	0	0	0.00

60 patients were analysed (Figure 1). Both groups (RS and RD) had similar demographic characteristics in terms of equal numbers of males and females, similar ages ranging from 18 to 60 years, and comparable characteristics in terms of patient height and weight (p value 0.05) (Table 1).

The mean time for sensory onset was 8.64±2.4 min in RS group versus 5.78±2.7 min in RD group (Table 2). The mean onset time for motor block was 10.42±3.6 min and 8.78±1.7min in RD group. The duration of sensory block was 323.65±21.23 min in RS group versus 446.24±29.84 min in RD group. The mean duration of motor block was 248.67±28.34 min in RS versus 276±18.65 min in RD group which was significant (p value <0.001). The time of first

rescue analgesic was 339.8±29.31 in group RS and 512.43±30.92 in group RD (p value<0.001). The quality of surgical anaesthesia was excellent in 10 patients in group RS and 16 patients in group RD (p value<0.001), good to intermediate in 20 patients in group RS and 14 patients in group RD (p value <0.001), poor in 2 patients (required conversion to general anaesthesia) in each group and hence they were excluded from the study (Table 3). No nerve block associated or dexmedetomidine-related adverse effects were reported. Patients in RD group were more sedated than group RS (Table 4). Excessive sedation, respiratory depression, nausea, vomiting, hypotension, or bradycardia was observed in neither group of patients (Table 5). Postoperative

clinical examination of patients revealed no impairment of sensory or motor function and no evidence or symptoms of nerve injury.

## Discussion

Various experimental, animal and clinical trials have investigated Dexmedetomidine as an additive drug for regional anaesthesia. Brummett et al. [17,18] reported that dexmedetomidine has sedative, analgesic, hemodynamic stabilizing properties and sympatholytic pharmacological effects. They also reported that addition of dexmedetomidine prolonged the duration of sciatic nerve block by using different long-acting local anaesthetic drugs in rats. They used alpha-2-adrenergic receptor agonist and reported increase in duration of thermal antinociception and analgesia in few animal studies. The perineural mechanism of action has also been confirmed by Brummett et al. [17] in animals. Brummett et al. [27] have also concluded that perineural dexmedetomidine added to Ropivacaine for sciatic nerve blockade in rats prolonged duration of analgesia by probably blocking the hyperpolarization-activated cation current and not by an  $\alpha_2$ -adrenoceptor antagonist. Centrally,  $\alpha_2$  agonists also inhibit the release of substance P in the nociceptive pathway, mostly at the level of the dorsal root neuron and by activation of  $\alpha_2$ -adrenoceptors in the locus coeruleus [28]. Multiple randomized controlled trials have been conducted since 2004, when dexmedetomidine was used [15] for the first time. A recent meta-analysis was conducted to examine its effectiveness as an additive to peripheral nerve block [29]. Abdallah et al. recently published a meta-analysis in which they examined four studies of dexmedetomidine as an additive for brachial plexus blocks [29]. The analysis concluded that addition of dexmedetomidine significantly prolonged mean motor block by 268 minutes and the time to first analgesic by 345 minutes. However, in their study the mean sensory block prolongation of 284 minutes was not statistically significant. The doses used in the four studies looking at brachial plexus blocks were 30mcg, 100mcg, 0.75mcg/kg, and 1mcg/kg. None of their studies examined in this analysis described hypotension as an adverse effect, and incidence of bradycardia was less than 10%. Our results are consistent with them.

Another recent study stated that the dexmedetomidine as an adjuvant to ropivacaine for cervical plexus block increased the duration of block

by approximately 50 minutes [30]. In another volunteer study, dexmedetomidine was added to Ropivacaine for ulnar nerve blocks and prolonged the analgesia by 200-minute [31]. In contrast, dexmedetomidine when administered systemically, increased the duration of analgesia by only 50 minutes. In another volunteer study, in which dexmedetomidine was added to Ropivacaine for posterior tibial nerve blocks, resulted in a prolongation of analgesia duration by approximately five hours [32]. Another recent study reported that the duration of sensory and motor block with dexmedetomidine as an adjuvant to bupivacaine supraclavicular blocks was almost twice as long, when compared to the addition of clonidine [33]. In our study, we have found that addition of Dexmedetomidine (50 $\mu$ g) to 20 ml of Ropivacaine 0.75% in ultrasound guided sciatic nerve block via popliteal approach resulted in quicker onset time for sensory and motor block, it prolonged the duration of both sensory and motor block and delayed time for first rescue analgesia and quality of anaesthesia was better when compared with Ropivacaine alone.

## Limitations of study

The small sample size of our study cannot assess for all efficacy and safety parameters of perineural dexmedetomidine administration. Dexmedetomidine use in patients with co-morbidities needs to be investigated further.

## Conclusion

Addition of dexmedetomidine to Ropivacaine resulted in early onset, prolongs duration of sensory block and delayed requirement of first analgesic in post operative period. Advantages like quicker onset and longer duration of nerve block can deliver both clinical and economic benefits in optimal patient care. However, further studies on perineural dexmedetomidine doses and their response, efficacy, and safety profile are needed.

*Conflict of Interest:* NIL.

## References

1. Marhofer D, Marhofer P, Triffiterer L, et al. Dislocation rates of perineural catheters: a volunteer study. *Br J Anaesth* 2013;111:800-06.

2. Aveline C, Le Hetet H, Le Roux A, et al. Perineural ultrasound-guided catheter bacterial colonization: a prospective evaluation in 747 cases. *Reg Anesth Pain Med* 2011;36:579-84.
3. Compère V, Rey N, Baert O, et al. Major complications after 400 continuous popliteal sciatic nerve blocks for postoperative analgesia. *Acta Anaesthesiol Scand* 2009; 53:339-345.
4. Ilfeld BM. Continuous peripheral nerve blocks: a review of the published evidence. *Anesth Analg* 2011; 113:904-25.
5. Axelsson K, Gupta A. Local anaesthetic adjuvants: neuraxial versus peripheral nerve block. *Curr Opin Anaesthesiol* 2009;22:649-654.
6. Bernard JM, Macaire P. Dose-range effects of clonidine added to lidocaine for brachial plexus block. *Anesthesiology* 1997;87:277-84.
7. Choi S, Rodseth R, McCartney CJ. Effects of dexamethasone as a local anaesthetic adjuvant for brachial plexus block: a systematic review and meta-analysis of randomized trials. *Br J Anaesth* 2014; 112:427-39.
8. Ammar AS, Mahmoud KM. Ultrasound-guided single injection infraclavicular brachial plexus block using bupivacaine alone or combined with dexmedetomidine for pain control in upper limb surgery: a prospective randomized controlled trial. *Saudi J Anaesth* 2012;6:109-114.
9. Casati A, Magistris L, Fanelli G, et al. Small-dose clonidine prolongs postoperative analgesia after sciatic-femoral nerve block with 0.75% ropivacaine for foot surgery. *Anesth Analg* 2000;91:388-392.
10. Erlacher W, Schuschnig C, Koinig H, et al. Clonidine as adjuvant for mepivacaine, ropivacaine and bupivacaine in axillary, perivascular brachial plexus block. *Can J Anaesth* 2001;48:522-525.
11. Hutschala D, Mascher H, Schmetterer L, et al. Clonidine added to bupivacaine enhances and prolongs analgesia after brachial plexus block via a local mechanism in healthy volunteers. *Eur J Anaesthesiol* 2004;21:198-204.
12. Magistris L, Casati A, Albertin A, et al. Combined sciatic-femoral nerve block with 0.75% ropivacaine: effects of adding a systemically inactive dose of fentanyl. *Eur J Anaesthesiol* 2000;17:348-53.
13. Trifa M, Ben Khalifa S, Jendoubi A, et al. Clonidine does not improve quality of ropivacaine axillary brachial plexus block in children. *Paediatr Anaesth* 2012;22:425-29.
14. Weber A, Fournier R, van Gessel E, et al. Epinephrine does not prolong the analgesia of 20 mL ropivacaine 0.5% or 0.2% in a femoral three-in-one block. *Anesth Analg* 2001; 93:1327-31.
15. Memis D, Turan A, Karamanlioglu B, Pamukcu Z, Kurt I. Adding dexmedetomidine to lidocaine for intravenous regional anesthesia. *Anesth Analg*. 2004; 98(3):835-40, table of contents.
16. Vieira PA, Pulai I, Tsao GC, et al. Dexamethasone with bupivacaine increases duration of analgesia in ultrasound-guided interscalene brachial plexus blockade. *Eur J Anaesthesiol* 2010;27:285-88.
17. Brummett CM, Norat MA, Palmisano JM, Lydic R. Perineural administration of dexmedetomidine in combination with bupivacaine enhances sensory and motor blockade in sciatic nerve block without inducing neurotoxicity in rat. *Anesthesiology* 2008; 109:502-11.
18. Brummett CM, Amodeo FS, Janda AM, et al. Perineural dexmedetomidine provides an increased duration of analgesia to a thermal stimulus when compared with a systemic control in a rat sciatic nerve block. *Reg Anesth Pain Med* 2010;35:427-31.
19. Esmoğlu A, Yegenoglu F, Akin A, Turk CY. Dexmedetomidine added to levobupivacaine prolongs axillary brachial plexus block. *Anesth Analg* 2010;111:1548-51.
20. Gandhi R, Shah A, Patel I. Use of dexmedetomidine along with bupivacaine for brachial plexus block. *Natl J Med Res* 2012;2:67-69.
21. Casati A, Fanelli G, Borghi B, Torri G. Ropivacaine or 2% mepivacaine for lower limb peripheral nerve blocks. Study Group on Orthopedic Anesthesia of the Italian Society of Anesthesia, Analgesia, and Intensive Care. *Anesthesiology*. 1999;90(4):1047-52.
22. Fanelli G, Casati A, Beccaria P, et al. A double-blind comparison of ropivacaine, bupivacaine, and mepivacaine during sciatic and femoral nerve blockade. *Anesth Analg*. 1998;87(3):597-600.
23. Dony P, Dewinde V, Vanderick B, et al. The comparative toxicity of ropivacaine and bupivacaine at equipotent doses in rats. *Anesth Analg*. 2000;91(6):1489-92.
24. Casati A, Fanelli G, Cappelleri G, et al. A clinical comparison of ropivacaine 0.75%, ropivacaine 1% or bupivacaine 0.5% for inter-scalene brachial plexus anaesthesia. *Eur J Anaesthesiol*. 1999;16(11):784-89.
25. Ramsay MA, Savege TM, Simpson BR, Goodwin R. Controlled sedation with alfaxalone-alphadolone. *Br Med J*. 1974;2:656-659.
26. Afonso J, Reis F. Dexmedetomidine: current role in anesthesia and intensive care. *Rev Bras Anesthesiol*. 2012;62:118-33.
27. Brummett CM, Hong EK, Janda AM, et al. Perineural dexmedetomidine added to ropivacaine for sciatic nerve block in rats prolongs the duration of analgesia by blocking the hyperpolarization-activated cation current. *Anesthesiology* 2011;115:836-43.
28. Shirasaka T, Kannan H, Takasaki M. Activation of a G-protein-coupled inwardly rectifying K<sup>+</sup> current and suppression of Ih contribute to dexmedetomidine-induced inhibition of rat hypothalamic paraventricular nucleus neurons. *Anesthesiology*. 2007;107:605-15.
29. Abdallah FW, Brull R. Facilitatory effects of perineural dexmedetomidine on neuraxial and

- peripheral nerve block: a systematic review and meta-analysis. *Br J Anaesth.* 2013;110(6):915-25.
30. Lin YN, Li Q, Yang RM, Mao ZX, Liu JC. Addition of dexmedetomidine to ropivacaine improves cervical plexus block. *Acta Anaesthesiol Taiwan.* 2013; 51(2):63-6.
31. Marhofer D, Kettner SC, Marhofer P, Pils S, Weber M, Zeitlinger M. Dexmedetomidine as an adjuvant to ropivacaine prolongs peripheral nerve block: a volunteer study. *Br J Anaesth.* 2013;110(3):438-42.
32. Rancourt MP, Albert NT, Cote M, Letourneau DR, Bernard PM. Posterior tibial nerve sensory blockade duration prolonged by adding dexmedetomidine to ropivacaine. *Anesth Analg.* 2012;115(4):958-62.
33. Swami SS, Keniya VM, Ladi SD, Rao R. Comparison of dexmedetomidine and clonidine (alpha2 agonist drugs) as an adjuvant to local anaesthesia in supraclavicular brachial plexus block: A randomised double-blind prospective study. *Indian J Anaesth.* 2012;56(3):243-9.
-